



Faculty of Medicine, Ramathibodi Hospital
MAHIDOL UNIVERSITY
Wisdom of the Land
Department of Pediatrics



Update Knowledge About Resistant Bacteria

Chonnamet Techasaensiri, MD
Division of Infectious Diseases
Department of Pediatrics
Faculty of Medicine Ramathibodi Hospital

Case

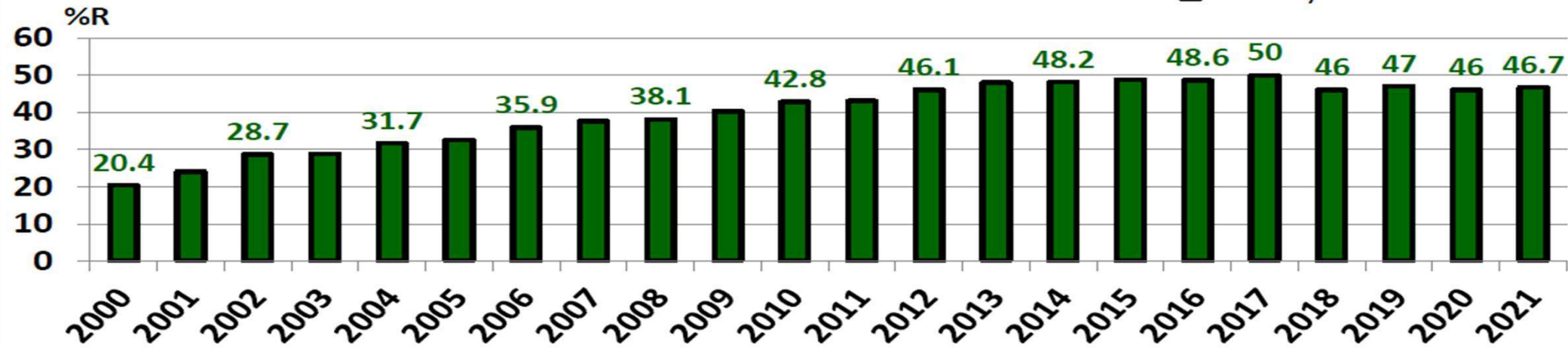
- 13 yo M from Home for Disabled Children with Down syndrome, congenital hypothyroidism
- Presented with **fever and respiratory difficulty** for 1 day.
- T 38.2°C, P 150/min, BP 131/71 mmHg, RR 35/min, O₂ sat 90%
- Lungs: coarse crepitations and rhonchi both lungs
- CXR: patchy infiltration at RML
- Initially pt was treated with levofloxacin then switched to meropenem and vancomycin due to septic shock.
- Pt died 1 day after diagnosed with septic shock.

Blood culture: *Klebsiella pneumoniae* CRE

ESBL producing *E. coli*

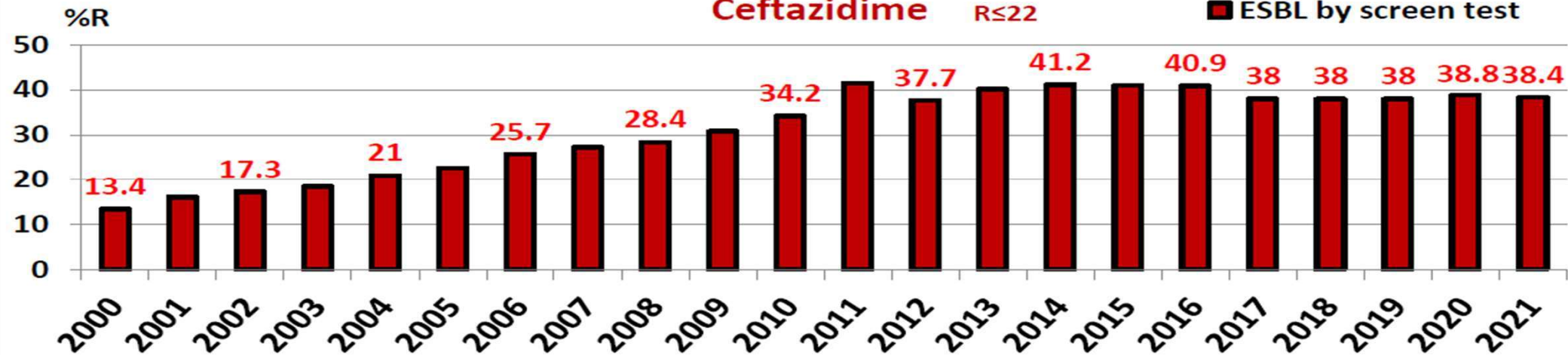
Cefotaxime R_{≤27}

■ ESBL by screen test



Ceftazidime R_{≤22}

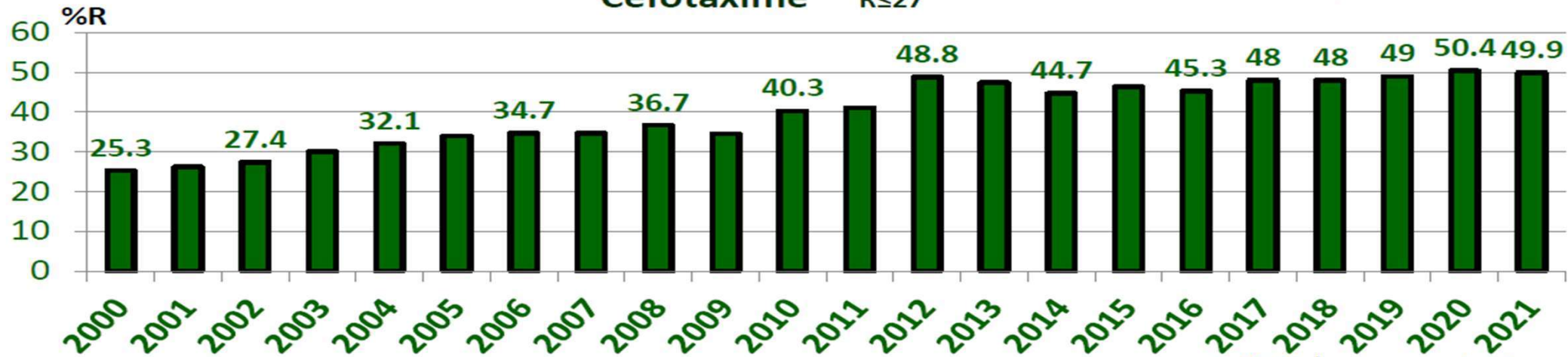
■ ESBL by screen test



ESBL producing *K. pneumoniae*

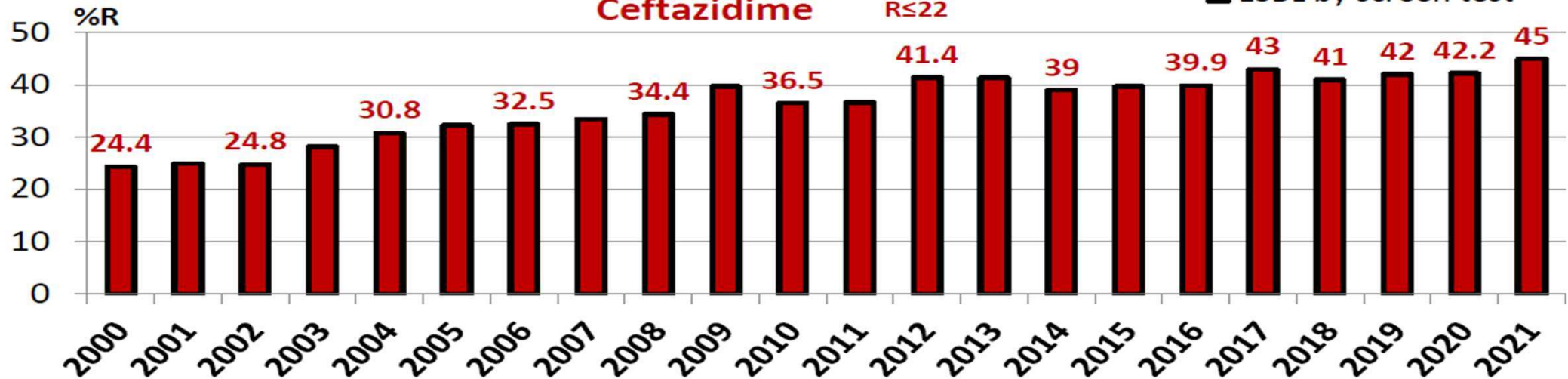
Cefotaxime R_s27

■ ESBL by screen test



Ceftazidime R_s22

■ ESBL by screen test



Carbapenem Resistance in *E. coli* and *K. pneumoniae*

