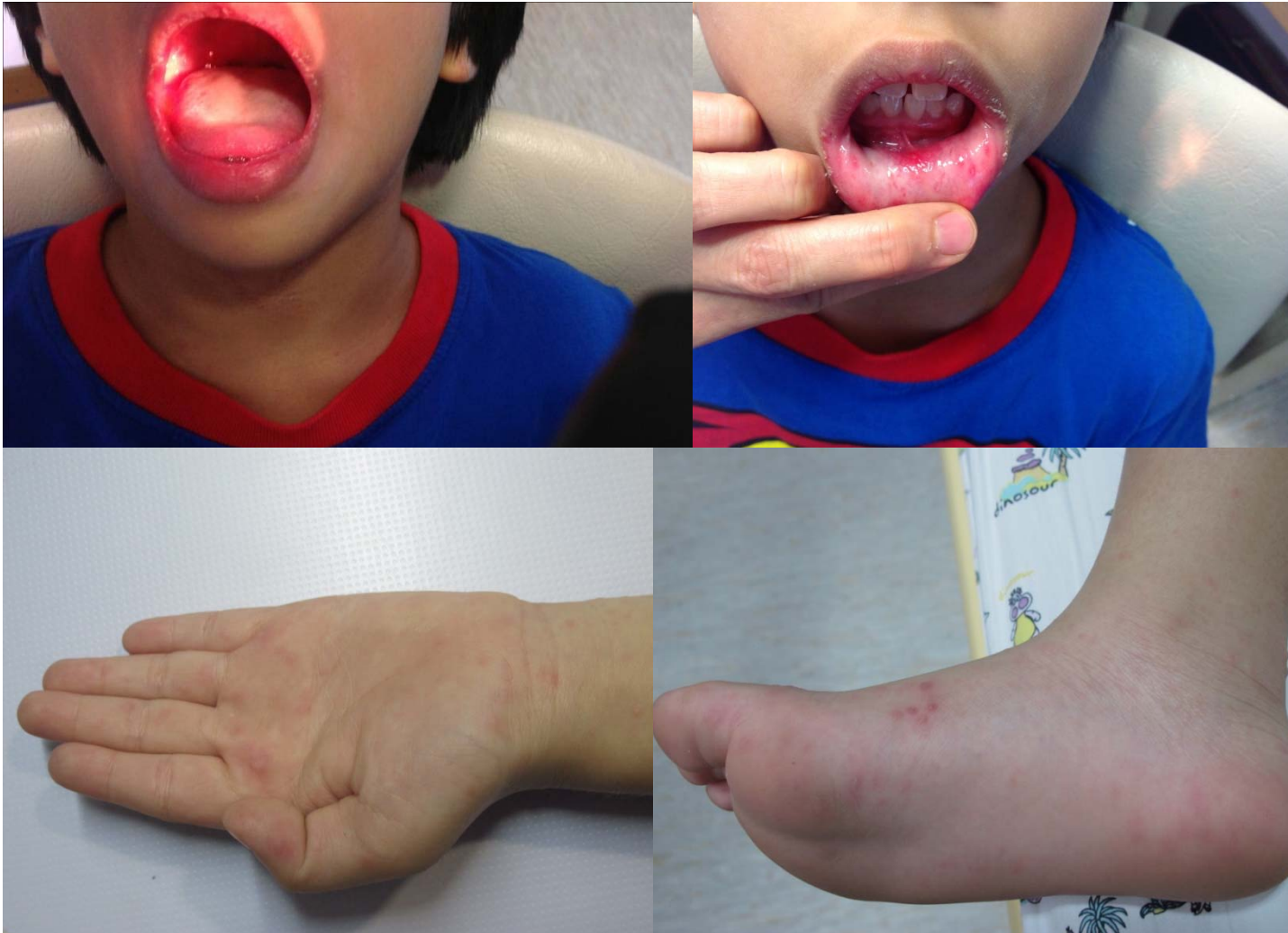

Hand Foot Mouth Disease



There is one more complication

- Under recognized
- Highly concerned by parents
- Unnecessarily treated

Between April 2012-Feb 2014, 3 children, age 2-4 years, presented with *nail changes* 3-4 weeks after clinical diagnosis of HFMD.

There was no history of nail trauma or significant medication.

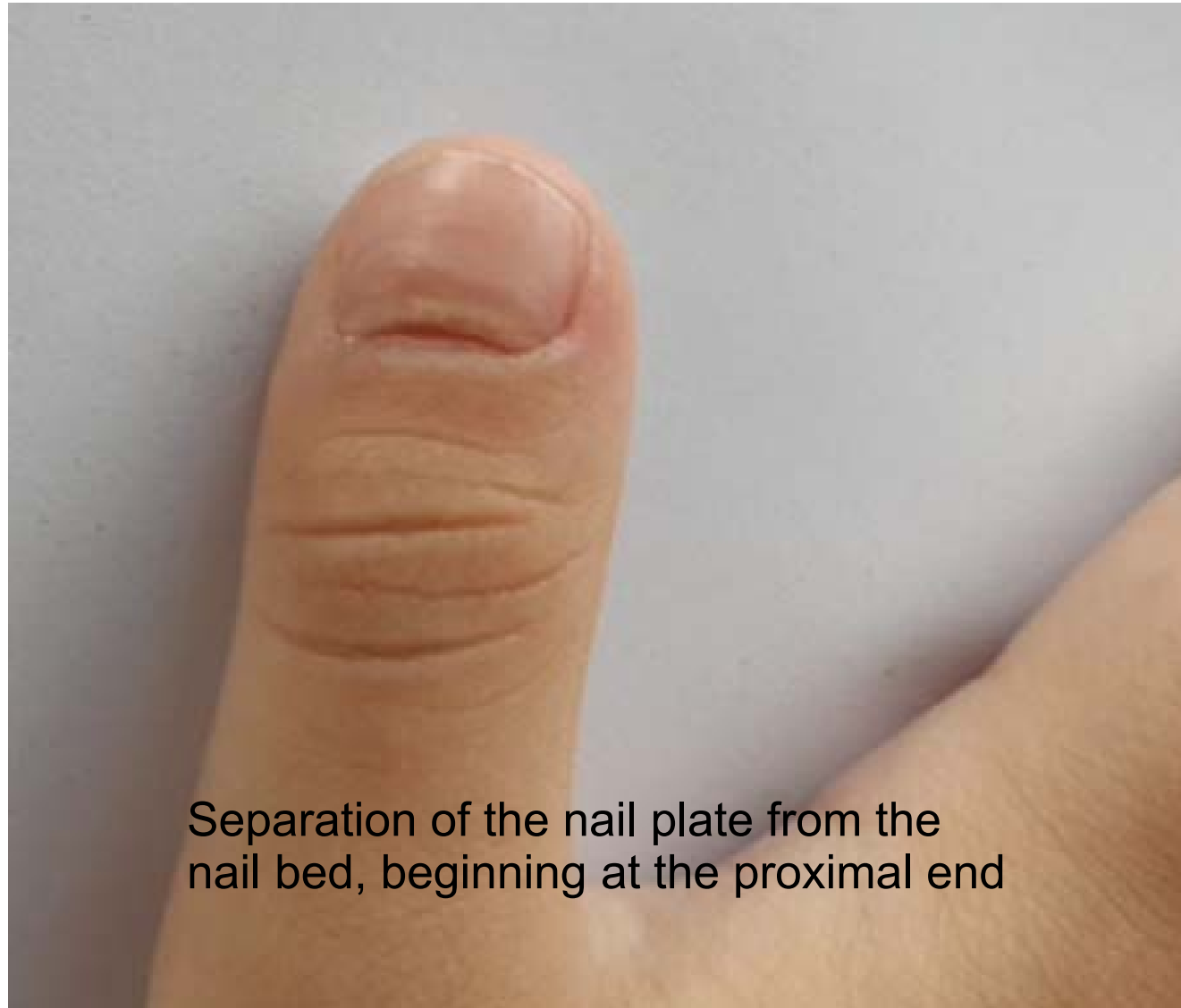
No periungual lesion during the acute viral skin manifestation.

Onychomadesis is defined as:

A painless, spontaneous separation of the nail plate from the nail bed, beginning at the *proximal* end.

It is a result of temporary cessation of nail formation.

There is subsequent shedding of the affected nails as the new nails grow.



Separation of the nail plate from the nail bed, beginning at the proximal end