

Symposium


Update on Antimicrobial Agents;
antibacterial, antiviral, antifungal and antiparasitic



Pukpen Sirikutt



Pornumpa Bunjongmanee



Noppadol Wacharachaisurapol



Nopporn Apiwattanakul

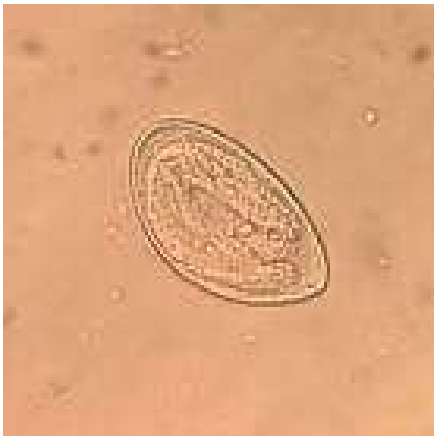Anti-Parasitic Drugs

Nopporn Apiwattanakul

**Department of Pediatrics, Faculty of Medicine
Ramathibodi Hospital, Mahidol University**

Case

- A 1-year-old boy presents with peri-anal itching.
- Physical examinations reveal peri-anal erythema, otherwise unremarkable.

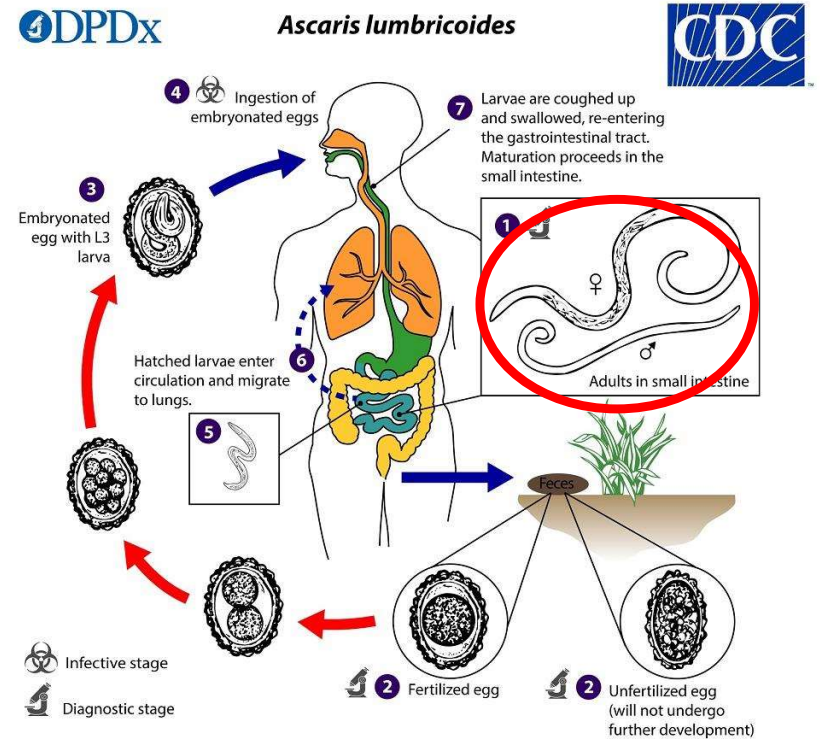
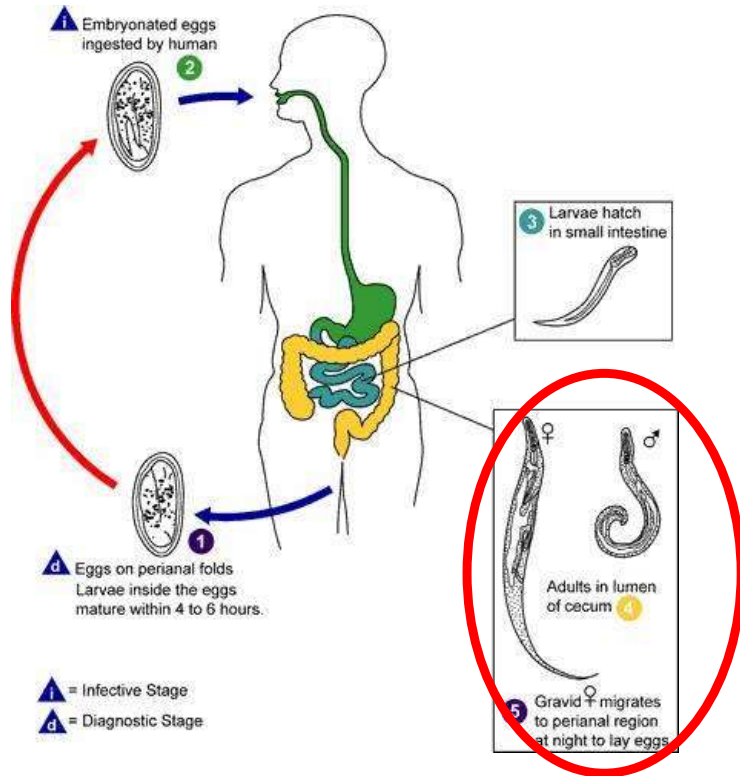


What is the diagnosis ?

What is the treatment of choice?

Case

- **Diagnosis : Enterobius vermicularis infection**
- **Treatment :**
 - Albendazole 200 mg orally one dose
 - Repeat with the same dose 2 weeks later
 - Use 400 mg/dose in children > 2 years old
 - Mebendazole not approved in children < 2 years old



E. Vermicularis Autoinfection

Albendazole : target adult worms