




Faculty of Medicine, Ramathibodi Hospital
MAHIDOL UNIVERSITY
Wisdom of the Land
Department of Pediatrics



คุณหมอชา ลูกหนูเจ็บปาก

Chonnamet Techasaensiri, MD
Faculty of Medicine Ramathibodi Hospital

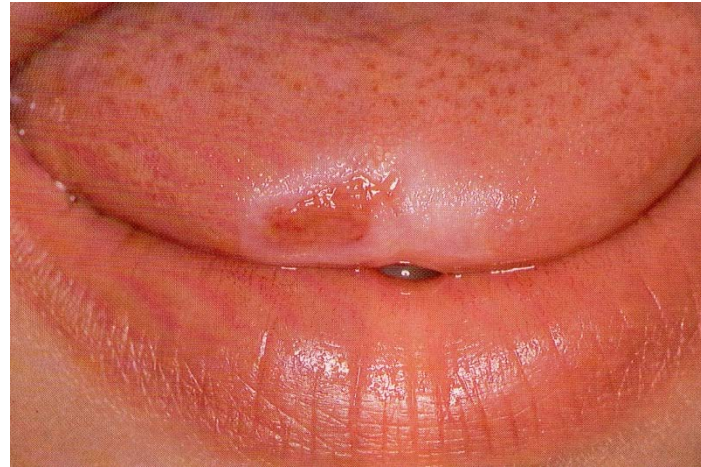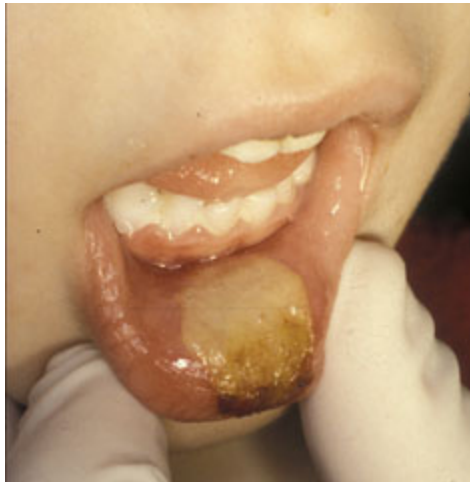Painful Oral Lesions

- ▶ Traumatic lesions and burns
- ▶ Aphthous ulcers
- ▶ Infections
 - ▶ Herpetic gingivostomatitis
 - ▶ Herpangina
 - ▶ Hand, foot, and mouth disease
 - ▶ Varicella
 - ▶ Oral candidiasis
- ▶ Behçet disease

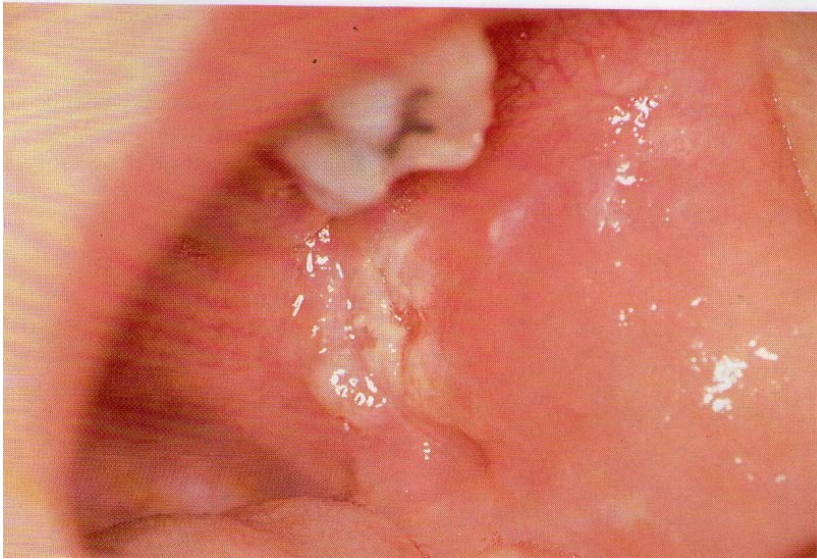


Traumatic Lesions and Burns

- ▶ **Traumatic ulcers: Most common oral ulcers in children**
 - ▶ Secondary to mechanical, chemical, or thermal injury
 - ▶ Running and falling with a foreign body in mouth can lead to an "ulcerative" lesion
- ▶ Lesions generally heal within 2 weeks.



Traumatic Lesions and Burns



- ▶ Chronic cheek biters and others w/ “self-abusive” behavior may require more comprehensive management, including bite guards, lip bumpers, extraction, and sedation



Aphthous Ulcers

- ▶ Etiology unclear although associated with many underlying conditions
- ▶ Stress, hormonal factors, infections, food hypersensitivity, immune irregularities, familial tendency all associated with occurrence
- ▶ Sodium lauryl sulfate found in many toothpastes has been linked to outbreaks
- ▶ Vitamin and mineral deficiencies may contribute

