

IVIIG in severe Enterovirus 71

: to give or not to give



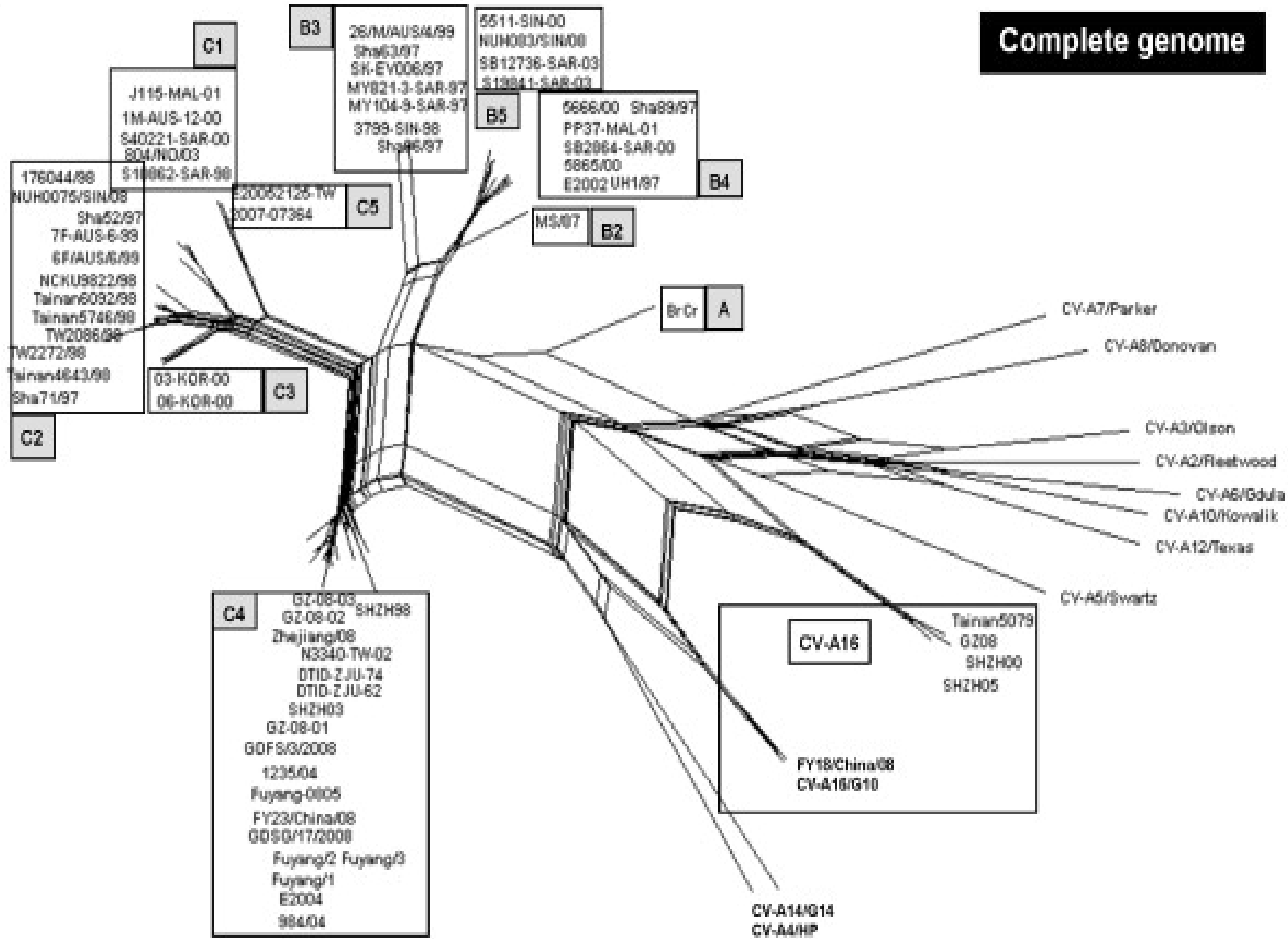
Umaporn Chantbuddhiwet, MD

Classification of Enteroviruses

- Polioviruses
- Coxsackieviruses A
- Coxsackieviruses B
- Echoviruses
- Enteroviruses



Complete genome



Clinical manifestation

- Mucocutaneous and respiratory manifestation
 - HFMD/Herpangina
 - Upper respiratory tract infection
 - Gastroenteritis
 - Non-specific viral rashes
 - Bronchiolitis/Pneumonia (young children)
- Neurological and systemic manifestation

Lancet Neurol 2010; 9: 1097-1105

Neurological syndromes associated with EV71 infection

	Frequency
Purely neurological manifestations	
Encephalitis, especially brainstem	Frequent
Acute flaccid paralysis (anterior myelitis)	Frequent
Encephalomyelitis	Frequent
Aseptic meningitis	Very frequent
Cerebellar ataxia	Infrequent
Transverse myelitis	Rare
Neurological and systemic manifestations	
Brainstem encephalitis with cardiorespiratory failure	Frequent
Manifestations indicative of immune-mediated mechanisms	
Guillain-Barré syndrome	Infrequent
Opsoclonus-myoclonus syndrome	Rare
Benign intracranial hypertension	Rare

Lancet Neurol 2010; 9: 1097-1105

