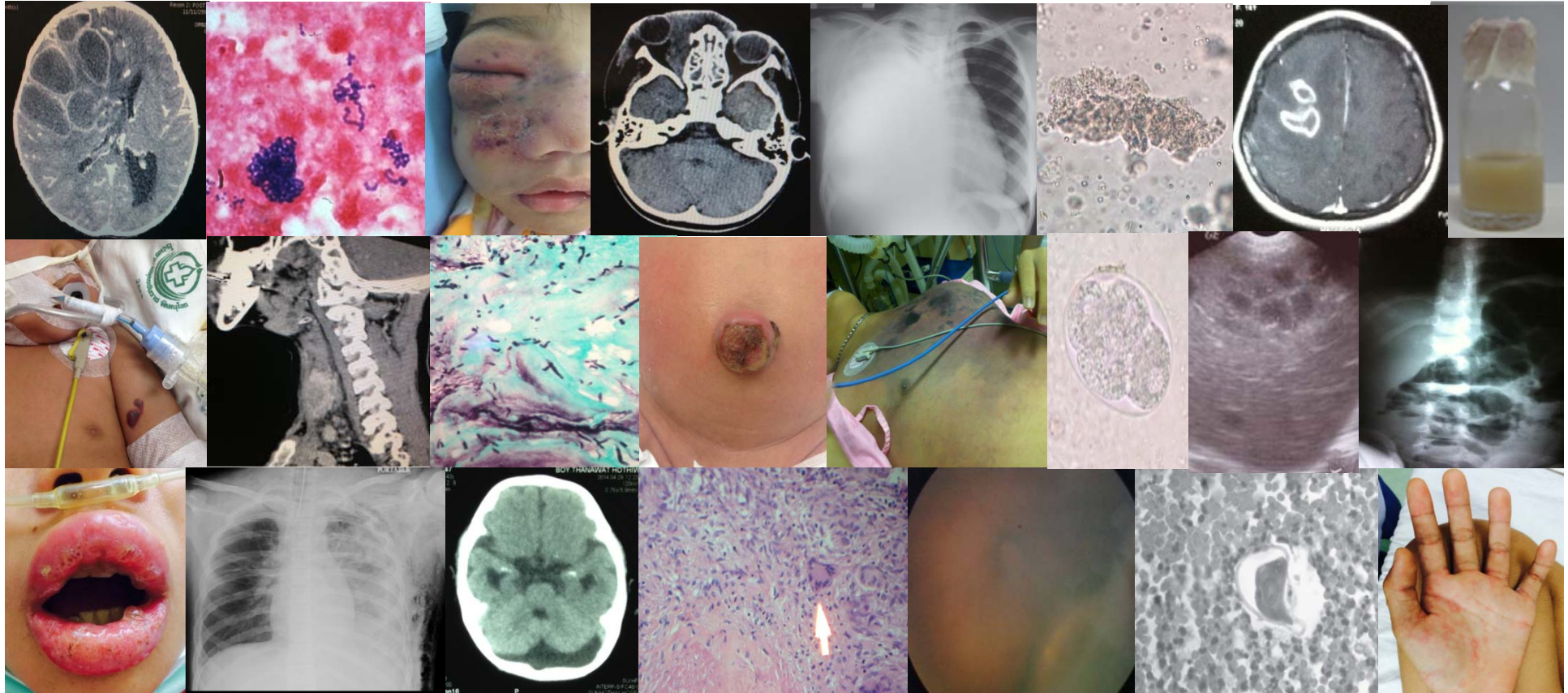


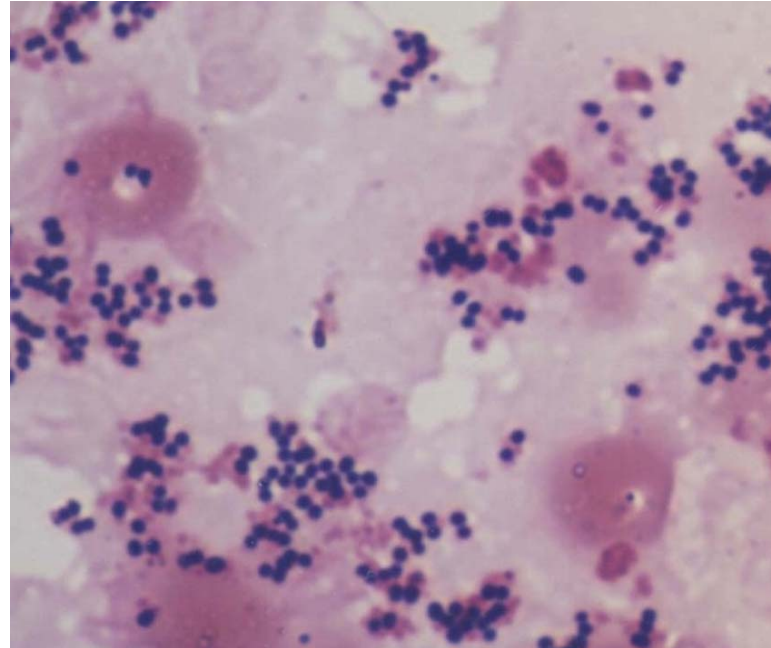
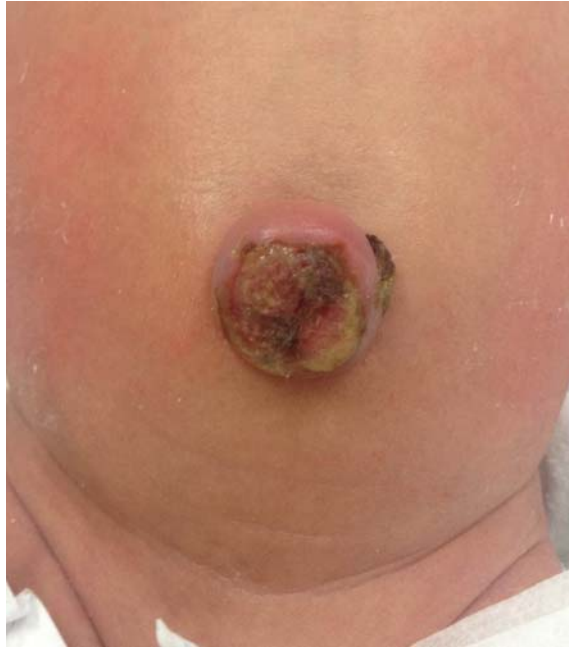PL-2 Photo Quiz in Pediatric ID



นพ.ทรงเกียรติ อุดมพรวัฒน์
โรงพยาบาลพุทธชินราช พิษณุโลก



1. เด็กอายุ 7 วัน, สะดือบวมแดง, มีหนองกลิ่นเหม็นใช้สูง



จงเลือกยาปฏิชีวนะ

ก. Ampicillin + Gentamicin

ข. Cefazolin

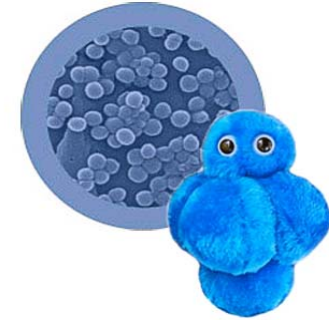
ค. Cloxacillin + Amikacin

ง. Unasyn

จ. Cefotaxime + Metronidazole



1.Omphalitis



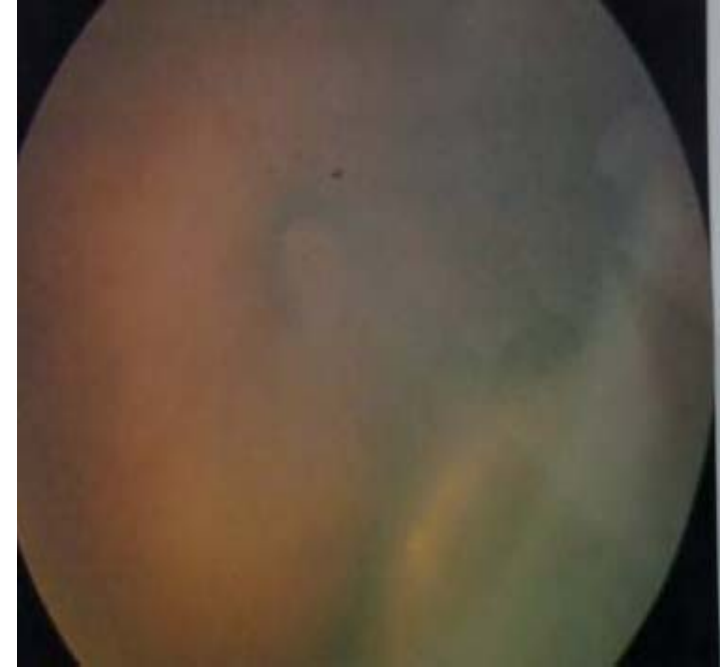
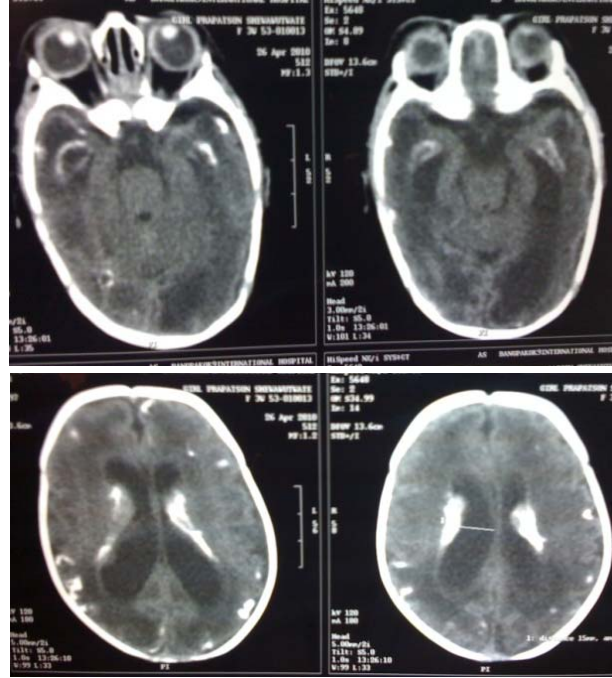
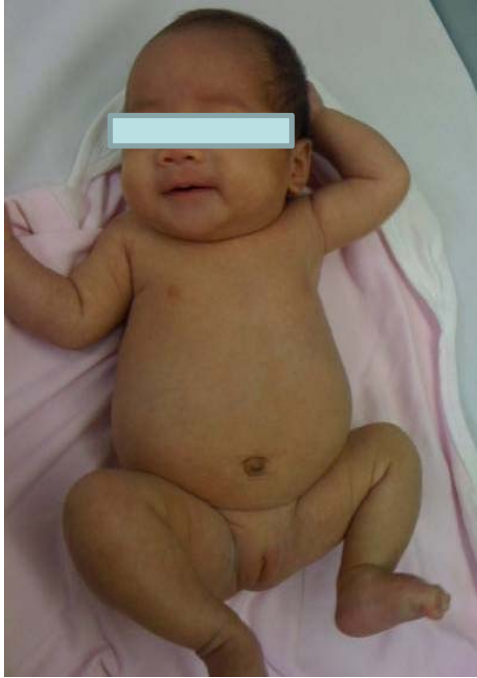1. Numerous	Staphylococcus aureus
2. Moderate	Group A beta-hemolytic Streptococci
3. Rare	Enterobacter cloacae *

-----1-2-3-----			-----1-2-3-----			-----1-2-3-----			-----1-2-3-----		
AMIKACIN.....	- - S	IMIPENEM.....	- - S	CLINDAMYCIN....	S S -	OFLOXACIN.....	- S -				
AMPICILLIN.....	- - R	CEFOPERA/SULB..	- - S	OXACILLIN.....	S - -	TETRACYCLINE...	- - -				
CEFAZOLIN.....	- - -	PIPERACI/TAZOB.	- - S	AMOXICIL/CLAV..	- - -	CEPHALOTHIN....	- - R				
CEFTAZIDIME....	- - R	CEFPIROME.....	- - -	PENICILLIN.....	R S -	CHLORAMPHENICOL	- - -				
CEFOTAXIME.....	- - I	ERTAPENEM.....	- - S	FOSFOMYCIN.....	S - -	LINEZOLID.....	- - -				
CIPROFLOXACIN..	- - S	MEROPENEM.....	- - S	RIFAMPICIN.....	S - -	TEICOPLANIN....	- - -				
GENTAMICIN.....	S - R	COLISTIN.....	- - -	VANCOMYCIN.....	S S -	TOBRAMYCIN.....	- - -				
NORFLOXACIN....	- - -	TIGECYCLINE....	- - -	CEFOXITIN.....	- - -	NEOMYCIN.....	- - -				
TRIMETHO/SULFA.	- - R	LEVOFLOXACIN...	S S -	FUSIDIC ACID...	S - -	POLYMYXIN B....	- - -				
AMPICILL/SULB..	- - S	ERYTHROMYCIN...	S S -	CEFTRIAZONE....	- S -	CEFTAZID/AVIBAC	- - -				


- **CDC:** < 30 days, redness/discharge+ culture (blood,omph)
- **Mixed** (*S.aureus, gr.A strep, E.coli, P.mirabilis*)
- **Risk:** LBW, intrapartum sepsis, home birth, hospital acqui
- Necrotizing fasciitis, myonecrosis, portal vein thombosis
- **Topical wound care:** mupirocin



2. เด็ก preterm 36 สัปดาห์ อายุ 1 เดือน จักษุแพทย์ส่งมา ปรึกษา (ตรวจROPหลังคลอด) พบ **chorioretinitis**



จงบอกเชื้อที่เป็นสาเหตุ



Toxoplasmosis

ค. **CMV**

จ. **Herpes simplex virus**

ข. **Rubella**

ง. **Syphilis**



2. Toxoplasmosis (โรคขี้แมว)

- **Triad:** Chorioretinitis, Hydrocephalus
Intracranial calcification
- **Pyrimethamine + Sulfadiazine + Leucovorin**
- **Corticosteroid:** CSF protein ≥ 1 g/dL and/or active chorioretinitis
- **Thai:** 1995-2013: 20 cases
 - 7 suspected, 25% complete triad
 - 1/5 deceased patients lived beyond age 13 yrs and died of a pulmonary infection.
 - All 15 surviving developed deafness, visual impairment or developmental delay.

